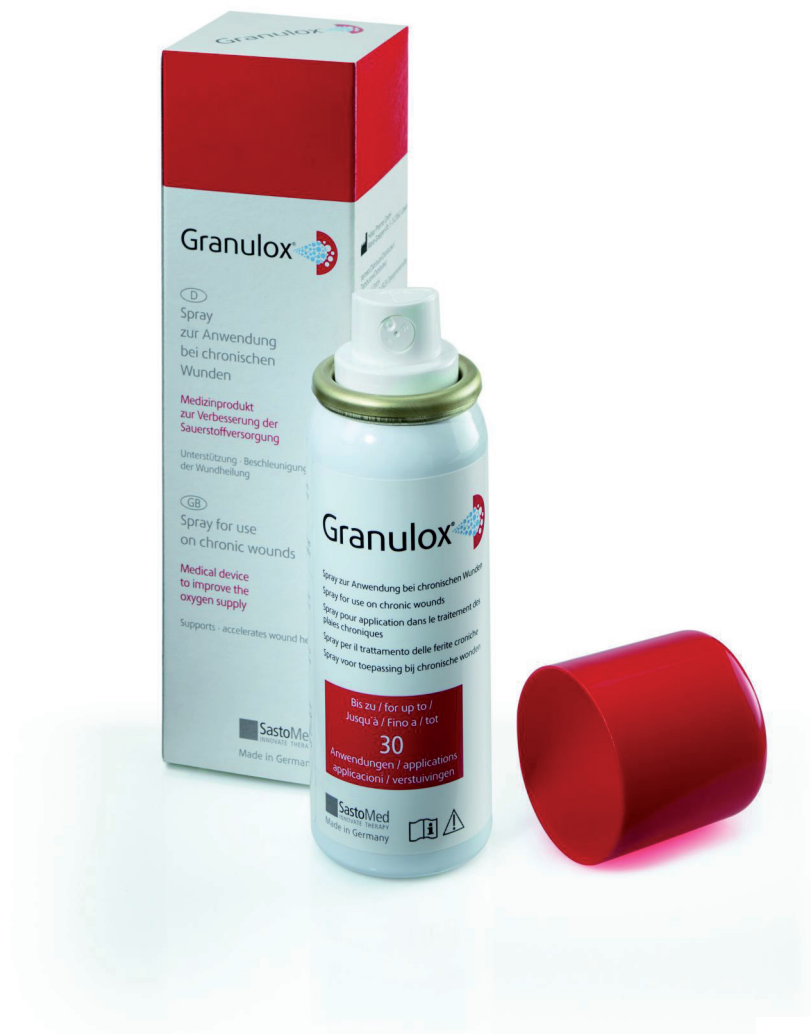



Use of Granulox® haemoglobin spray in clinical practice: case report series



CASE REPORT 1

This case shows how the introduction of Granulox into the treatment regimen of a longstanding ischaemic wound in a patient who had diabetes and an unhealthy lifestyle managed to put the wound on a healing trajectory.

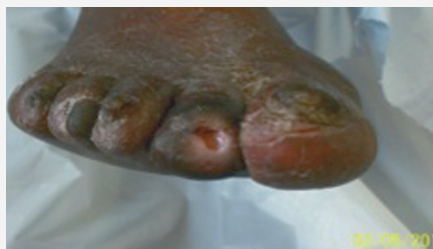

Figure 1.
The wound on 2 May, 2014 after debridement of the wound base.

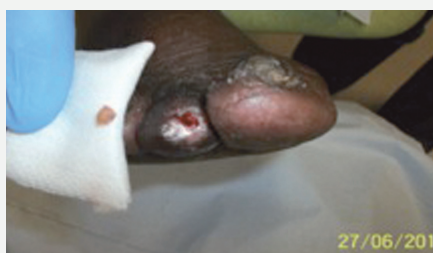

Figure 2.
On 27 June, 2014 — a fragment of bone removed from the wound.

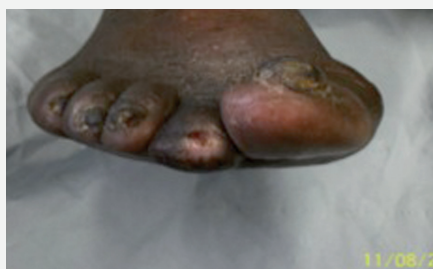

Figure 3.
On 11 August, 2014 — there has been a decrease in wound width and depth.

This 85-year-old male patient had a history of type 2 diabetes going back for over 30 years. His assessment also revealed that he smoked 10–15 cigarettes per day and drank alcohol (whisky) on a daily basis.

The author found that he had an ischaemic wound to the apex of the second toe on his right foot (Figure 1), which had been in place for over 12 months (before the team decided to begin treatment with Granulox® [infirst Healthcare]). Previous treatments included silver-containing dressings (Aquacel® Ag; ConvaTec) and dressings that incorporated honey (Medihoney®; Dermasciences), as well as various foam dressings.

At one of the twice-weekly debridement sessions the author noted a pocket of yellow pus trapped around the bone at the wound's base, although there was no necrosis in the wound. There was also no pulse below the patient's knee. Despite this, the surgeons were unwilling to perform a bypass operation to re-route bloodflow to the area mainly because they felt that — due to his age and smoking history — the patient might not survive the three-and-a-half-hour operation.

As mentioned above, the patient was being reviewed twice-weekly to debride the area and release the build up of pus in the wound. At these visits, the wound was debrided, cleansed, photographed and redressed. Due to his diabetes and ischaemia, it was felt that leaving the wound for any longer than a few days at a time might mean that an infection could develop and spread undetected.

STARTING ON GRANULOX®

Initially, the team began treating the patient with Granulox twice-weekly from 13 March, 2014. Granulox was chosen due to a lack of healing progress when using various other product, as well as the unwillingness of the surgeons to operate. The author felt that Granulox's ability to provide oxygen

to the wound bed might prove crucial to healing.

On 27 June, 2014 the bone at the base of the wound was removed with a scalpel and sterile forceps (Figure 2). It had become loose and the team felt that removing it would give the wound a better chance of healing.

By 11 August, 2014 this patient had received 41 applications of Granulox. It was decided to continue treatment as substantial improvement had been noticed, including decreased wound size and reduced pain (Figure 3). For example, on 13 March, 2014 the wound measured 4x5cm, whereas on 11 August, 2014 it measured 2x2cm — an 80% reduction. The patient's pain level also significantly reduced from '7' to '4' on a verbal pain scale of 1–10 (where '10' was the worst pain imaginable).

Finally, at a visit on 13 October 2014, the wound appeared to be completely healed and remains so at the time of writing. Unfortunately, the patient has developed another wound on the little toe of his left foot, which is currently being treated with Granulox and Activheal® Foam (Advanced Medical Solutions).

CASE REPORT 2

Six weeks of treatment with Granulox resulted in healing of a chronic ischaemic wound that had been present for over a year. The use of Granulox also reduced the pain that the patient was experiencing and the volume of exudate being produced.

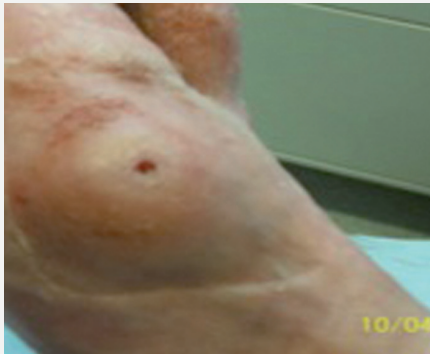

Figure 1.
The wound on 10 April, 2014, one week after starting treatment with Granulox and following debridement.

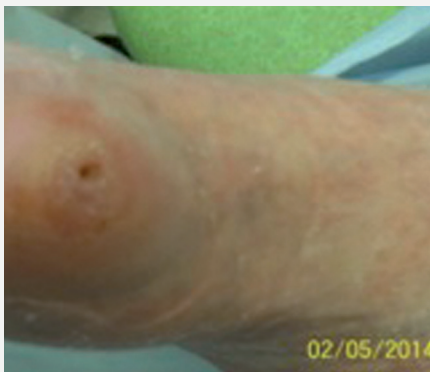

Figure 2.
On 2 May, 2014 the surrounding callus has been reduced and there was also a reduction in wound depth.

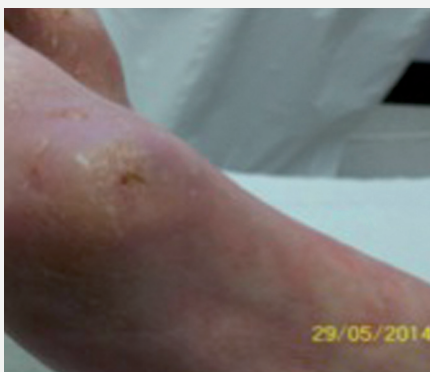

Figure 3.
The wound on 29 June, 2014, two weeks after wound closure had been achieved.

This 83-year-old male patient had a complicated medical history including registered blindness, poor hearing and a propensity to falls. He was also hypertensive and smoked up to 10 cigarettes a day. He was seen by the author as he had developed an ischaemic foot ulcer to the side of his right metatarsal phalangeal joint, which had been present since December, 2013.

The author noted that there was a lack of healing from the base of the wound bed, where a callus had formed over the ulcer — pus would also exude from the wound whenever it was debrided.

The patient had already been seen by vascular surgeons, who had indicated that the risks of surgery outweighed any potential gains, mainly due to the patient's age and smoking history. A number of treatments had been tried in an effort to heal the wound, including combinations of Iodoflex® (Smith & Nephew) and Activheal Foam; Aquacel Ag and Activheal Foam; and Inadine® (Systagenix) and Activheal Foam.

STARTING ON GRANULOX®

The team decided to start treatment with Granulox on 3 April, 2014, partly due to the fact that other products had not progressed healing and the theory that Granulox might improve the transportation of oxygen to ischaemic areas of the wound bed. At this time, the wound measured 2x2cm and was stagnant with no improvement since January 2014.

In the coming weeks, the patient reported that the pain from the wound lessened; similarly, the author recorded that there was a reduction in volume of exudate and that the wound had started to granulate.

The wound achieved complete closure on 15 May, 2014 after six weeks and 12 applications of Granulox. There was no longer a cavity in the skin, or any pus being produced, and, despite some callus formation, there was no scar tissue present.

CASE REPORT 3

This patient's quality of life significantly improved when Granulox promoted the healing of two large ulcers on his foot, which had been causing considerable pain. Previous dressings used had compounded his condition by causing maceration to the periwound skin and pain at dressing change.

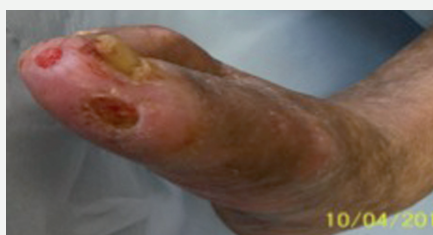

Figure 1.
The wounds on 10 April, 2014, two-and-a-half weeks after starting Granulox.

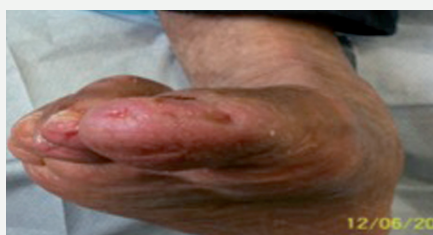

Figure 2.
On 12 June, 2014, the wounds have decreased in size and exhibit 100% granulation rather than a thin layer of creamy adherent slough.

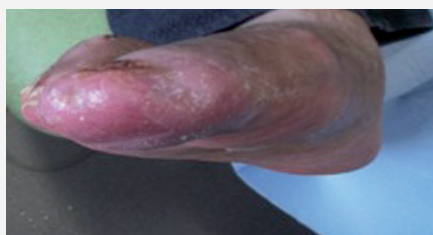


Figure 3.
Wounds at 7 August, 2014 — one week after stopping Granulox, the ulcers remained resolved and the patient was applying emollient cream daily.

This 63-year-old male had severe deformities caused by rheumatoid arthritis affecting both his hands and feet. As well as smoking between 5 and 20 cigarettes per day, he also experienced episodes of anxiety and was taking steroids for his rheumatoid arthritis. He walked with the aid of a wheel-based walking frame and had high cholesterol and hypertension.

The patient was seen by a vascular consultant and a narrowing of the tibial artery below the right knee was diagnosed. This had led to the development of two large ulcers on the apex and side of the right big toe (hallux). The wound on the medial side of the toe measured 14x9mm, while the wound on the apex of the toe measured 6x9mm. The wound beds contained a thin layer of 100% creamy adherent slough, but there was no necrosis or maceration.

The patient was being seen twice-weekly and various dressings had been tried, including Activon® Tulle (Advancis Medical); UrgoClean® (Urgo Medical); Iodoflex; and Inadine — all in combination with Activheal Foam.

However, there were a number of problems during these dressing combinations, including maceration and pain on removal.

STARTING ON GRANULOX®

It was decided to start the patient on Granulox on 24 March, 2014. Granulox was chosen due to the ischaemic nature of the wounds, which it was felt might benefit from the oxygen-donating properties of the product. Also, the patient was experiencing a lot of pain at dressing removal and when the wounds were being cleansed with saline. The team had been told by other patients that Granulox had reduced their pain levels.

After a couple of weeks' treatment with Granulox, the creamy adherent slough in the wound beds began to dry up, making it possible to gently debride it with a scalpel (Figures 1 and 2). The patient reported less pain in the wound and was sleeping

better. There was also no odour from the wounds.

WOUND CLOSURE ACHIEVED

Both wounds eventually achieved closures within 12 weeks. The wound on the apex of the toe resolved on 28 July, 2014 after a total of 34 applications of Granulox; the other ulcer was resolved on 27 June after 27 applications. In both cases, the ulcer cavity was completely filled and a thin layer of callus had formed, which once removed, revealed healthy fresh epidermis and an absence of scarring.

CASE REPORT 4

This case presents two traumatic heel wounds that were causing the patient considerable pain — to the extent that she had to set an alarm to wake during the night to take painkillers. Granulox helped to reduce the number of painkillers being taken and promote epithelialisation after 17 applications.

This patient was a 49-year-old female who smoked roll-up cigarettes but was in otherwise general good health. She had sustained two traumatic wounds through using acid treatment to reduce the hard skin on her heels — she then self-treated with plasters which stripped off a layer of skin when removed.

Even though the wounds themselves were only a couple of millimetres deep and there was no clinical infection, they were painful on walking and even when the patient supported her calf with a pillow she still experienced shooting pain (scoring '11' on a scale of 1–10, with '10' being the worst pain). She was taking tramadol, paracetamol and ibuprofen every four hours (eight of each tablet per day), which constituted a large dose of painkillers.

When she was first seen, she was setting her alarm to wake herself up at night to ensure that she took her pain medication regularly. Her dressings (Mepilex; Mölnlycke Health Care) were being changed on a Monday and Thursday in a dedicated woundcare clinic, and at each treatment a podiatrist would clean the wounds with saline. However, this also caused a great deal of pain.

STARTING ON GRANULOX®

Granulox was selected as the previous dressing had stuck to the wound slightly, and it was felt the liquid nature of Granulox might prevent some of this sticking as well as promoting healing. Similarly, patient experience suggested that Granulox reduced pain, which in this case could have helped to reduce the amount of painkillers the patient was taking.

It was decided to start treatment with Granulox on 16 June, 2014. At this point the right heel wound measured 24x78mm, while the left heel measured 22x77mm.

The right heel wound achieved complete closure in eight weeks after 16 applications of Granulox. The use of Granulox also helped to reduce the pain that this patient was experiencing (she now reported pain as being '4' on a scale of 1–10, where 10 was the worst pain). The tissue within the wound bed also dried up and was replaced with normal epidermal growth.

The left heel wound reduced in size from 22x77mm on 16 June, 2014, to 11x46mm on 11 August, 2014 (a reduction of 73%) following 17 Granulox treatments. The fragile-looking red granulation tissue had started to dry up and the patient was experiencing far less wound pain.

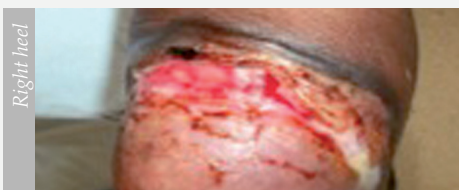

Figure 1.
On 19 June, 2014 three days after starting treatment with Granulox.

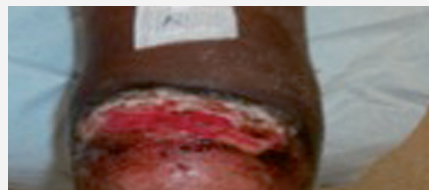

Figure 2.
On 3 July, 2014 showing reduced maceration at the wound edges.

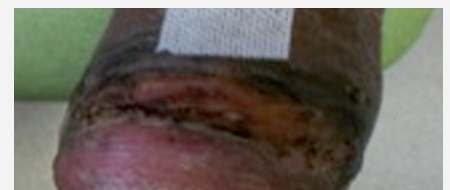

Figure 6.
On 11 August, 2014, the wound had resolved.

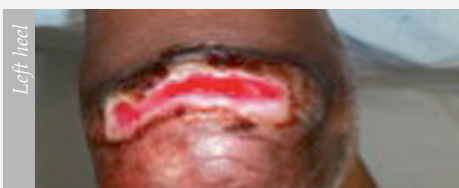

Figure 4.
On 19 June, 2014 three days after starting treatment with Granulox.

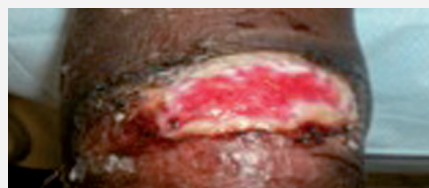


Figure 5.
On 3 July, 2014 showing reduced maceration at the wound edges.

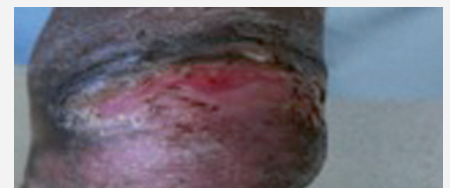

Figure 6.
At the time of writing the left heel had not completely healed and treatment with Granulox was continuing.

CASE REPORT 5

The patient in this case had a history of drug abuse that had resulted in a chronic leg ulcer of four years' duration. Eight weeks of treatment with Granulox reduced the wound's size and, more importantly, had a positive impact on the patient's daily life.

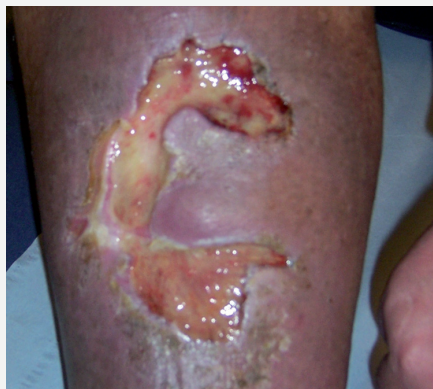

Figure 1.
Patient's leg ulcer showing areas of slough and excoriated periwound skin.

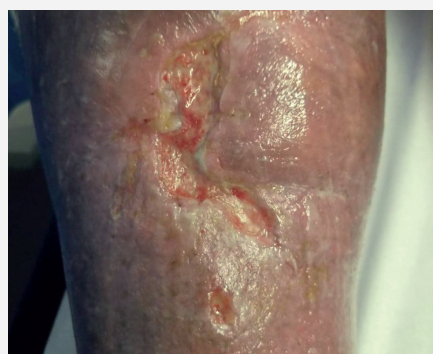

Figure 2.
Wound showing size reduction and growth of granulation tissue.

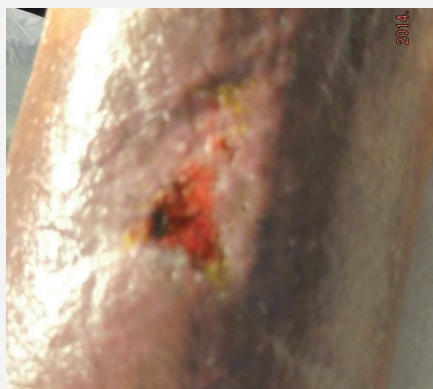

Figure 3
Towards the end of the treatment period, the wound had reduced significantly in size and showed extensive epithelialisation.

This patient was a 47-year-old male who had been diagnosed with chronic venous insufficiency (CVI) following recurrent episodes of deep vein thrombosis (DVT) as a result of continuous intravenous drug use. This resulted in oedema and he had been living with a chronic leg ulcer for more than four years, with several episodes of wound deterioration.

Before being seen by the author, the patient was being visited twice-weekly by a practice nurse and a range of dressings had been tried on his wound, including honey and silver dressings, and a charcoal dressing to combat the malodour. He had also undergone Doppler assessment to determine his ankle brachial pressure index (ABPI) before being placed on a two-layer compression system (KTwo®; Urgo Medical). However, during the past four years the ulcer had gone through different phases of healing without ever being completely resolved (Figure 1).

At the time of writing, the patient had given up his drug use and taken a day job in a rehabilitation unit as a counsellor. However, having a painful leg constantly impacted on his day-to-day life and he was embarrassed about the malodour emanating from the wound.

Due to an increase in pain, odour and exudate volumes, the patient became non-compliant with the compression therapy, removing the bandages every few days. At this point he was referred to the author for reassessment and advice.

At the author's assessment, it became clear that the patient's main goal was to improve his quality of life by minimising the pain and healing the ulcer. On inspection, the wound itself measured 10x6x1.0cm and was critically colonised with 100% grey slough. There was also malodour and high volumes of yellow/brown exudate. The periwound was also red and excoriated (Figure 1). The patient stated that he was experiencing significant pain (scoring '8' on a scale of 1–10, with '10' being the worst pain).

As the grey-coloured slough clearly indicated lack of oxygen and the wound bed had been stagnant for too long, the patient was started on a haemoglobin spray-on solution (Granulox®) along with the same dressing regimen. Granulox was sprayed directly into the wound bed from a distance of 5cm. Due to the high volume of exudate, the wound was then covered with a highly absorbent pad (KerraMax Care®; Crawford Healthcare), as well as an activated charcoal dressing to reduce malodour. The surrounding skin was then moisturised with an emollient before the compression bandaging was again applied from toe to knee.

Going forward, the plan was to continue with the new regimen, with weekly dressing changes. Figure 2 shows the wound bed after three weeks' treatment with Granulox. The wound now measured 10x5x0.5cm, with 50% sloughy tissue. The periwound skin was drying out and the exudate had turned clear and amber-coloured. The patient's pain score had reduced to '5' and the charcoal dressing was discontinued, as the odour had also been considerably reduced.

The wound continued to improve until the final consultation at week eight, by which time there was 100% granulation tissue in the wound bed and the overall wound size had reduced to 1.5x1.0cm. There was no sign of infection, the periwound skin was healthy and the exudate volume was low. Similarly, the patient's pain level had reduced to '1'. Granulox was continued until the final stages of healing and the patient was moved into compression hosiery, as both the oedema and exudate volumes were being well controlled (Figure 3).

The patient declared himself happy that after four years in compression bandages he could now wear shorts and go to the beach. He no longer felt embarrassed about odour from the wound and felt generally more confident, even getting a new counselling job. He was also free of pain and had stopped taking tramadol and ibuprofen.

CASE REPORT 6

This case shows how a dehiscent sternal wound that was not responding to treatment with antimicrobial dressings, progressed to healing after eight weeks' treatment with Granulox. Granulox also improved activities of daily living, as previously, odour and excess exudate had prevented the patient from socialising.

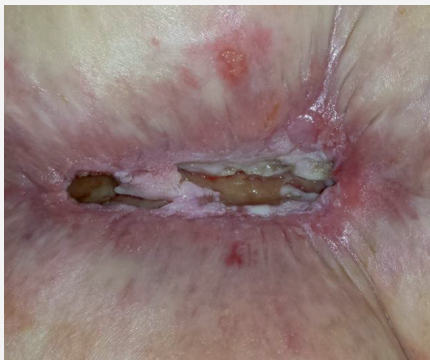

Figure 1.
Sternal wound showing extensive slough and macerated periwound skin.

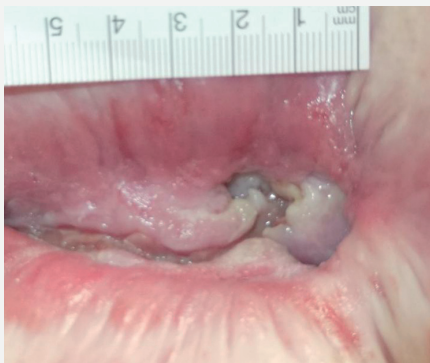

Figure 2.
Wound at 29 April, 2014 showing reduced slough and converging edges.

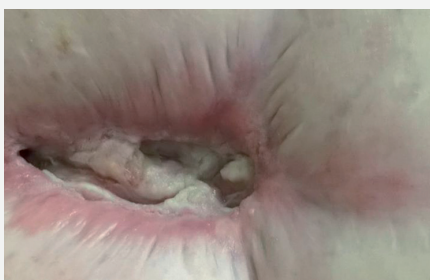

Figure 3.
Wound on 25 June, 2014 demonstrating much-reduced size and improvements to periwound skin.

This 60-year-old female patient had undergone an emergency sternotomy six years previously. Due to her recurrent ill-health — including a history of cardio-pulmonary respiratory disease (COPD), hypertension, myocardial infarction and tracheostomy — the wound had undergone several episodes of infection, which required intravenous antibiotics. The sternal wound had now dehiscent and was not responding to treatment with antimicrobial dressings containing both honey and silver. The wound had significantly disrupted the patient's quality of life and her dressings were being changed daily by district nurses to address the odour and excess exudate, which prevented her from socialising.

Despite alternating between honey and silver dressings, the district nurses were unable to achieve healing — the exudate was not being contained and the tissue in the wound bed had a thick, dull and yellow appearance. It was also malodorous.

When the patient was referred to the author the wound measured 9x5x1.5cm (Figure 1). The wound bed was 'stagnant' and comprised 100% sloughy tissue, with cloudy, highly viscous exudate. The sternal bone was also visible. The wound was critically colonised and the surrounding skin was red, macerated and excoriated. The patient stated that she was experiencing significant pain (scoring it '8' on a scale of 1–10, with 10 being the worst pain).

STARTING ON GRANULOX®

The author began daily treatment with a haemoglobin spray-on solution (Granulox®). This product was chosen because the wound bed showed little sign of adequate oxygenation despite the previous attempts to remove biofilm. Granulox was applied directly to the wound bed after it had been soaked for five minutes in Prontosan® (B Braun) solution, then the previously used antimicrobial dressing was applied. The secondary dressing was reassessed in an attempt to contain the exudate more effectively, and it

was decided to use a foam dressing. At a review of the wound at week three of treatment, the author found that there was no malodour and the patient reported that the dressing was staying drier for longer periods of time. The wound size had reduced to 7.5x2x0.5cm, and the tissue type appeared healthier than it had two weeks previously. Even though the wound was still critically colonised, the wound bed exhibited only 50% slough, with the other 50% comprising red granulation tissue. The periwound skin was still red, but was no longer macerated. Crucially for the patient, the exudate was now thinner, there was no malodour and her pain score had reduced to '5'.

At week eight of treatment with Granulox, the wound was reassessed and now exhibited 100% granulation tissue. The size of the wound had also reduced to 6x1.5x0.2cm, and while not completely healed, there was no evidence of critical colonisation. Similarly, the periwound skin had also improved and the exudate production was now only medium and clear-coloured. There was still no odour and the pain score had reduced to '1'.

IMPACT ON PATIENT QUALITY OF LIFE

Significantly, the patient's quality of life had vastly improved — she stated that she could now 'dress up' to go out without feeling embarrassed or anxious about odour or exudate. She also found it easier to go about her everyday business as the district nurses now only needed to visit twice-weekly for dressing changes and she had even been away with her family for an entire week.

From the author's clinical perspective, the wound size and exudate production were significantly reduced in the treatment time and this had cost implications as fewer district nurse visits were required. Importantly, the patient's quality of life was significantly improved.







The case reports included in this document explore the use of Granulox® haemoglobin spray (infirst Healthcare) for the treatment of patients with chronic and acute wounds. The importance of oxygenation and tissue perfusion to the wound-healing process have been well researched (Bishop, 2008), and it is recognised that oxygen demand increases during the process of tissue repair (Howard et al, 2013). However, underlying comorbidities that patients with wounds might have, such as chronic venous insufficiency (CVI), peripheral artery occlusive disease and diabetes, lessen the oxygen supply via the vascular system. In addition, oxygen from outside might be prevented from reaching the wound bed due to the physical barrier of exudate production. Haemoglobin naturally binds and then releases oxygen. Thus, the use of Granulox, a water-soluble, red haemoglobin spray, allows oxygen to be uniformly distributed in exudate, where it binds oxygen from the surrounding air and carries it to the wound bed, diffusing it into cells. In this way, an increased supply of oxygen is provided to accelerate and support wound healing.

The wounds included in this series of case reports demonstrate the versatility and ease of use of this new treatment modality. In addition, the positive impact that Granulox had on patient quality of life can be seen by the patients' reduction in pain and improvements in activities of daily living, as their longstanding wounds started to heal.

REFERENCES

Bishop A (2008) Role of oxygen in wound healing. *J Wound Care* 17(9): 399–402

Howard MA, Asmis R, Evans KK, Mustoe TA (2013) Oxygen and wound care: a review of current therapeutic modalities and future direction. *Wound Rep Regen* 21(4): 503–11

Summary of case evaluations						
Case reports	Patient comorbidities	Wound type, location and duration (if known) at presentation	Patient pain rating at presentation *	Patient pain rating at the end of the evaluation *	Results seen after introducing Granulox®	Time to wound healing after introduction of Granulox®
 Case 1	Diabetes, unhealthy lifestyle	Ischaemic toe wound, >12 months' duration	7	4	Wound steadily decreased in size. Pain levels also reduced	7 months
 Case 2	Blindness, propensity to falls, hypertension, smoker	Ischaemic foot ulcer, 16 months' duration			Reduction in pain and exudate volume	6 weeks
 Case 3	Rheumatoid arthritis, smoker, high cholesterol levels, hypertension	Two ulcers on the toe			Reduction in pain and odour, slough in wound beds dried up, facilitating gentle debridement	12 weeks
 Case 4	Smoker	Traumatic heel wounds to both feet	11	4	Reduction in pain and promotion of epidermal growth	Right heel healed after 8 weeks; left heal continuing to progress to healing
 Case 5	Chronic venous insufficiency, deep vein thrombosis, previous history of drug abuse	Chronic leg ulcer, 4 years' duration	8	1	Steady improvement in wound tissue, and volume and colour of exudate. Increased patient confidence	8 weeks
 Case 6	Cardio-pulmonary respiratory disease, hypertension, myocardial infarction	Dehiscenced sternal wound	8	1	Reduction in odour and exudate volume significantly improved patient quality of life	While not completely closed, by week 8 wound exhibited 100% granulation tissue

* where '1' = least pain and '10' = worst pain on a verbal pain scale

The case reports in this document were kindly provided by Mike Green, Diabetes Specialist Podiatrist, Birmingham Community Healthcare NHS Trust (case reports 1–4) and Luxmi Mohamud, Tissue Viability Clinical Nurse Specialist, Guys and St Thomas NHS foundation Trust (case reports 5–6). Patient permission was given for all photographs taken.

The views expressed in this document are those of the authors and do not necessarily reflect those of the *Journal of Community Nursing* or infirst Healthcare Ltd.